

# The Diagnostic Value of Computer-assisted Post-processing Technique of CT Colonography for Patients with Colorectal Cancer

CHIH-WEI YU<sup>1</sup> YI-KANG KU<sup>1</sup> CHUNG-WEI LEE<sup>1</sup> YUK-MING TSANG<sup>1</sup> JANE CHIEN-YAO HSU<sup>1</sup>  
TA-CHENG WEI<sup>2</sup> TE-HUNG WANG<sup>3</sup> CHAO-WEN WENG<sup>3</sup>

*Department of Medical Imaging<sup>1</sup>, Surgery<sup>2</sup>, Internal Medicine<sup>3</sup>, National Taiwan University Hospital*

To evaluate the respective diagnostic value of computer-assisted post-processing applications in computed tomographic (CT) colonography for patients with colorectal cancer.

Thirty four patients with colorectal cancer diagnosed by conventional colonoscopy and/or barium enema examination underwent CT colonography prior to operation. These data were all acquired from a spiral CT scanner and were sent to a separate workstation for further evaluation. Four post-processing applications of volume rendering techniques including Multi-planar Reconstruction (MPR), Quick\_colon, CutPlane\_colon, and Fly-through Navigation were evaluated. The diagnostic performance of each application in localization, extraserosal invasion, regional lymph node involvement, and surface characterization was analyzed by a subjective grading score.

Each of the volume rendering techniques had respective value preoperatively in different ways: MPR application clearly demonstrated the whole extent of the lesion and it offered additional enhancement pattern and extraserosal information. Fly-through application offered an intraluminal visualization of the lesion simulating conventional colonoscopy. Surface unevenness, luminal constriction, and the fungating nature of the lesion were shown clearly. A colonic fold which could mimic a

projecting lesion in axial images could easily be excluded by this technique. Quick\_colon application demonstrated the exact spatial location and extent of the lesion from the whole segment of colon simulating conventional double contrast study. CutPlane\_colon application slaved a 10 mm thick data into a composite image that offered both two-dimensional (2D) and three-dimensional (3D) information on a single image. Finally, we found that MPR had the overall highest score in lesion detection and demonstration among these post-processing applications.

Among the post-processing applications in CT colonography, MPR is the best in lesion localization and demonstration. Other three applications serve a supplementary role in diagnosis.

**Key words:** Colorectal cancer; Computer-assisted Post-processing; CT colonography; Virtual colonoscopy

Computed tomographic (CT) colonography is a rapidly evolving technique for detection of colorectal cancer in recent years [1-3]. Using a fast spiral CT and under breath holding, the entire abdomen from the liver to rectum can be scanned after per-rectal air insufflation. It is less painful, technically less difficult than conventional colonoscopy [4, 5], and less skill-dependent than barium enema exam. In addition to interpreting the axial images, various techniques of computer-assisted volume rendering have been introduced hoping to aid in clinical diagnosis. Our purpose was to evaluate the diagnostic value of post-processing applications in computer-assisted CT colonography for patients with colorectal cancer.

Reprint requests to: Dr. Yuk-Ming Tsang  
Department of Medical Imaging, National Taiwan University Hospital.  
No. 7, Chung Shan S. Road, Taipei 100, Taiwan, R.O.C.

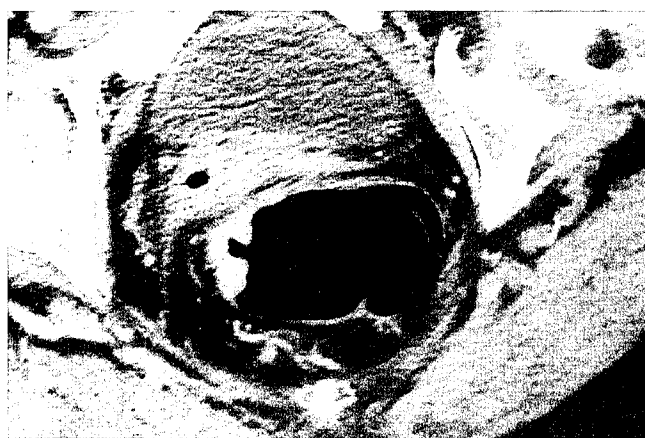

## MATERIALS AND METHODS

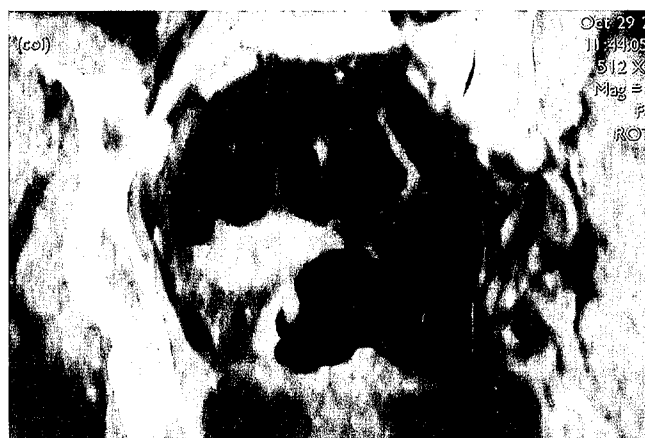From September 2001 to March 2002, 34 patients (ages ranged from 32 to 67 years old; M: F = 21:13; total 38 lesions) who were suspected to have colorectal lesion by previous conventional colonoscopic examination (n = 34) and/or barium enema study (n = 27) underwent CT colonography before colorectal surgery. The results were all correlated with the surgical findings and histopathological reports. All of these 38 lesions were proved to be colorectal cancer. The previously suspected polyps by colonoscope or barium study were all proved to be benign lesions and were not included in our study.

For optimal colonic cleansing, all patients received a standard colonoscopic bowel preparation prior to CT scan. We did not apply bowel relaxant routinely [6]. The patients were placed on the CT table in supine position at first. A rubber tube was inserted into the rectum and the colon was insufflated manually with room air to the patient's maximum tolerance. CT scan was performed on a HiSpeed Advantage CT

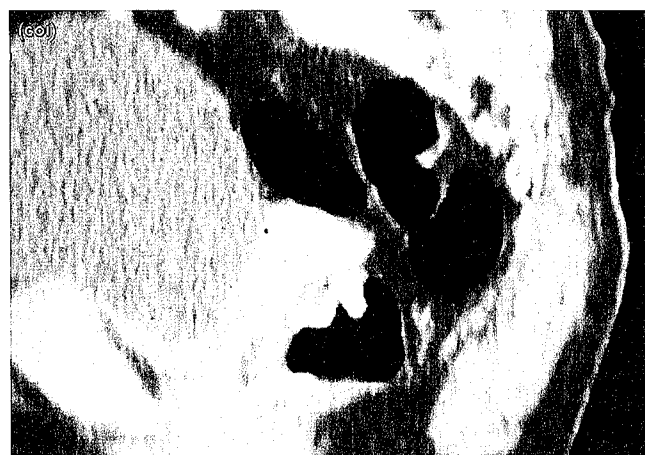scanner (General Electric Medical System, USA). A scout CT image of the abdomen was obtained first to verify adequate bowel distention. The supine set of images were obtained with low mA of 50 and 120 kVp. Then the prone set of images were obtained at 120 kVp, 200 to 250 mA, 3mm collimation, pitch of 1.5, and 1 or 1.5 mm reconstruction interval in prone position. Intravenous contrast medium (Ultravist, 100 mL; injection rate 2.0 to 2.5mL/sec) was routinely used immediately before this high resolution scan because it offers better diagnostic confidence [7]. The supine and prone sets of images were routinely obtained in each case for comparison for better diagnostic information and to exclude fecal interference [8]. All CT images were then transferred to a separate workstation (Advanced Windows workstation 3.1, General Electric Medical System). This workstation was equipped with various post-processing applications for colorectal application including: (i) 2D Multiplanar Reconstruction (MPR); (ii) Quick\_colon; (iii) CutPlane\_colon; (iv) Fly-through Navigation. First, MPR consists of reformatted oblique axial,



1a



1b



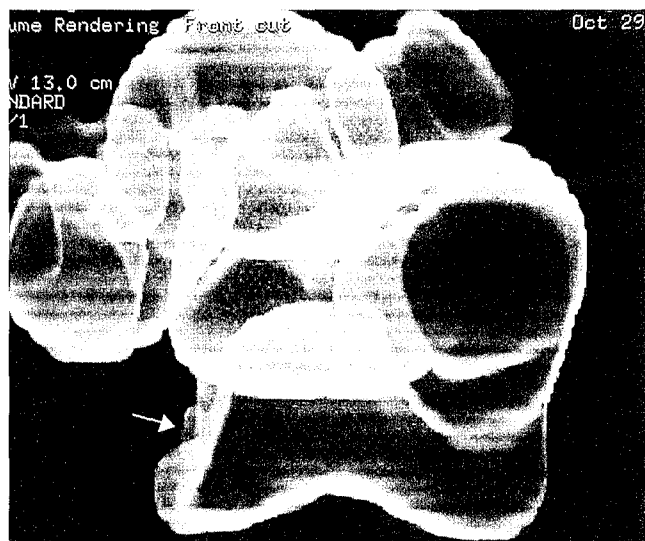
1c

**Figure 1.** MPR consists of reformatted multi-direction demonstration. **a.** Axial image. A true lesion often revealed abnormal enhancement, presence of extraserosal infiltration (arrowhead), and regional lymph nodes (arrow) on MPR images; **b.** Coronal image; **c.** Sagittal image.

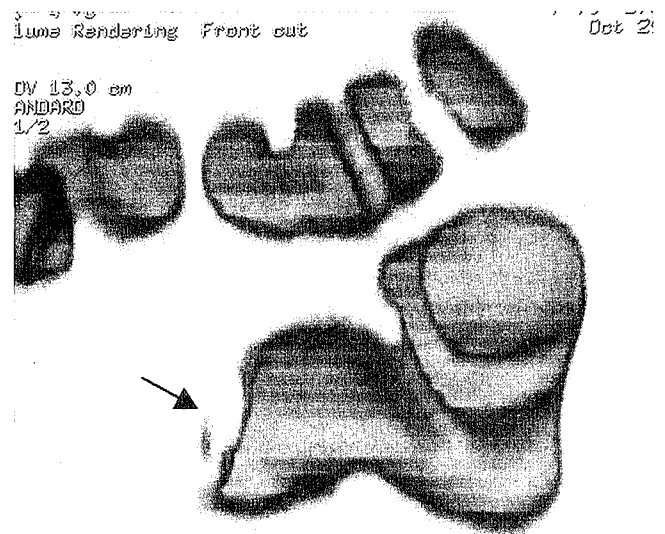
coronal, and sagittal images at multi-direction demonstration (Fig. 1). Second, Quick\_colon technique simulated the conventional double contrast barium study that enabled see-through colonic wall in addition to the profile (Fig. 2a). Third, CutPlane\_colon technique slabs a 10 mm thick data into a composite image in various views that offered both 2D information of that plane and 3D information of the luminal surface of the colon on a single image (Fig. 2b). Fourth, Fly-through Navigator technique provides a volume-rendered intraluminal view which simulated an endoscopic view (Fig. 2c). During the Fly-through Navigator evaluation, a subwindow of a targeted sectional view of the colon would always present at the corner so that the spatial location inside the lumen can be correlated with the anatomical colonic position.

All of these images were interpreted directly on the workstation by two radiologists (visiting staffs) independently. For a typical study, it would take 15 to 20 minutes for the scanning phase and about one to one and half an hour for the evaluation phase. Any inconsistency encountered between the two radiologists was resolved by consensus. As the scanning phase was performed by a technician and a resident, the radiologists who underwent the evaluation phase were not aware of lesion location reported by previous colonoscope or barium study. These interpretations consisted of two steps: 1. Review of MPR images to localize a lesion. 2. Evaluate of all applications.

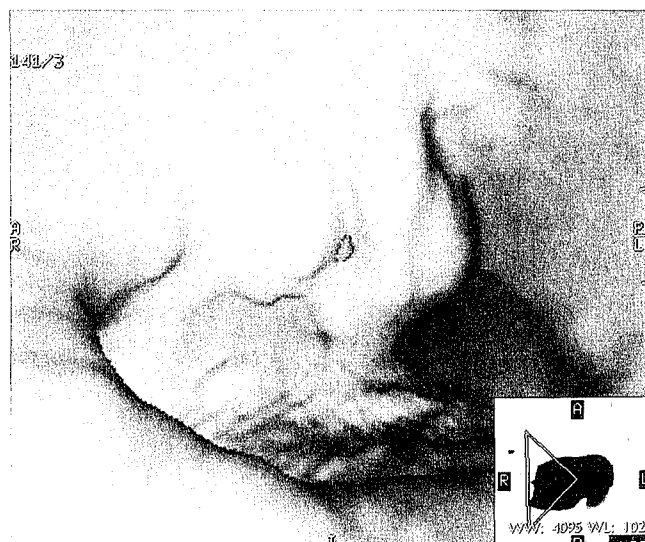
For analyzing the diagnostic performances of these four applications, the ability to demonstrate a lesion in different ways was compared: the ability to



2a



2b



2c

**Figure 2.** a. Quick\_colon technique simulated the conventional double contrast barium study. b. CutPlane\_colon technique slabs a thick data into oblique images. c. Fly-navigation technique provided a volume-rendered intraluminal view. A subwindow of a targeted sectional view is always present.



show and localize a lesion, to demonstrate the presence of extraserosal infiltration, to exclude the involvement of regional lymph node, and to characterize the surface of a lesion. However, since the Fly-through Navigation application could only show the endoluminal information, the presence of extraserosal invasion, and the regional lymph node involvement would not be available by this technique; and because the Quick\_colon offered only see-through view of colonic wall, the information about the presence of extraserosal invasion, regional lymph node involvement, and the surface character would not be available by this technique. In order to quantify the diagnostic performance of each application in different criteria, a three-point grading score was used: 3, excellent: the lesion could be well demonstrated by the single application without the hint from other application(s); 2, diagnostic but not excellent: the lesion could be well demonstrated by the application with the hint from other application(s); 1, probable and questionable: the images revealed suspicious abnormality by the application with the hint from other application(s); 0, non-visible: the lesion could not be identified even with the hint from other application(s). Score would be subjectively for each application and the results would be calculated and compared with each other. A Student-Newman-Kauls test was used to obtain p values and statistical significance at  $p < .01$  was determined.

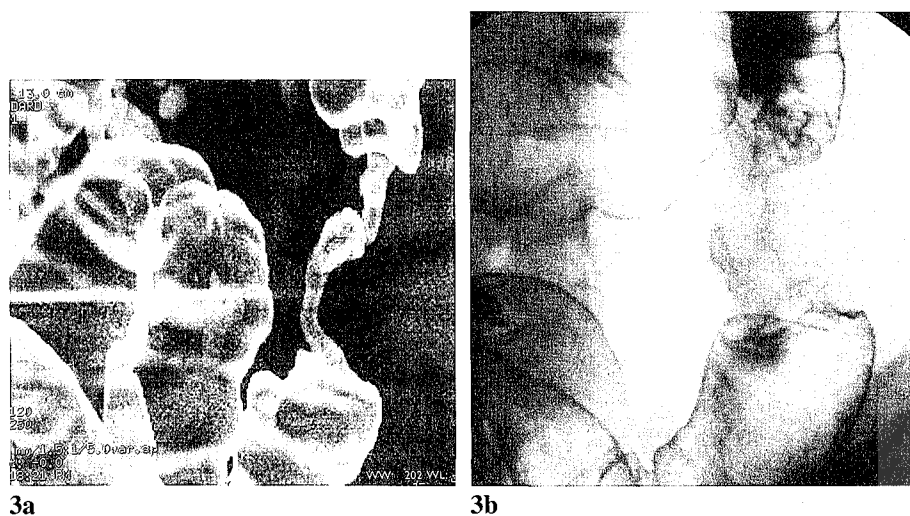
## RESULTS

The maximal diameter of these lesions was ranged from 1.1 to 9.8 cm (mean 6.6 cm). After correlated with pathological result, the overall sensitivity, specificity, and positive predict value of our CT

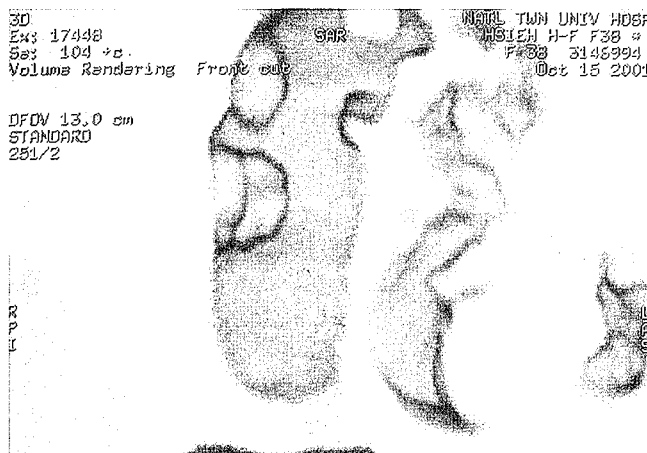
colonography was about 97.4, 90.5, and 94.9% respectively.

Each of the volume rendering techniques had respective diagnostic value in different ways. MPR application together with IV contrast enhancement clearly demonstrated the extent of the lesion, enhancement pattern, extraserosal stranding, and regional lymphadenopathy, in addition to presence of hepatic metastasis. A true lesion often revealed abnormal enhancement, presence of extraserosal infiltration, or even regional lymph nodes on MPR images (Fig. 1a). Quick\_colon application demonstrated the exact spatial location and extent of the lesion with respect to the whole segment of colon simulating conventional double contrast study. The change of the adjacent mucosa, such as focal mucosal irregularity or segmental narrowing, was well demonstrated using this technique. A true lesion also presented as a persistently nondistended segment of colon, with focal asymmetric or circumferential change of profile in Quick\_colon images (Fig. 3). CutPlane\_colon application conjoined both 2D and 3D information. Whole extent of the lesion and the surface mucosal change could be evaluated on one single view. Fly-through Navigation application offered a multi-directional intraluminal view of the lesion simulating conventional colonoscopy. The intraluminal view of mucosal surface could be evaluated. If a suspected lesion had an irregular surface, abrupt margin, and/or deformity of adjacent haustral fold on Fly-through Navigation images or CutPlane\_colon images, a true lesion would be more likely (Fig. 4).

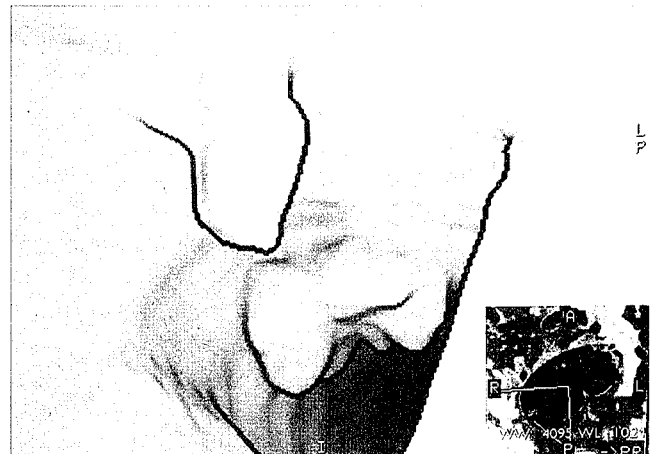
The performance scores of each technique were summarized in Table 1. Since Fly-through Navigation only gave lumen/surface information, localization,



**Figure 3. a.** A lesion at descending colon presented as a persistently non-distended segment of colon in Quick\_colon image. **b.** Double contrast barium study of the same patient revealed a similar appearance of segmental narrowing.



4a



4b

**Figure 4.** **a.** A true lesion often had abrupt margin and irregular surface on CutPlane\_colon image. **b.** Fly-through navigation image of the same patient also revealed similar appearance.

**Table 1.** The diagnostic performance in different post-processing techniques:

	MPR		Quick_colon		CutPlane_colon		Navigation		
	Score mean	Rank sum	Score mean	Rank sum	Score mean	Rank sum	Score mean	Rank sum	p value
Localization	2.711	117	1.684	73	2.237	96.5	na*		< .01
Extraserosal invasion	2.527		na		1.974		na		< .01
Regional LN involvement	2.368		na		1.710		na		< .01
Surface characterization	1.263	68.5	1.605	81	2.316	111.5	2.447	119	< .01

\* na: not available

The ability to detect liver metastasis is only available in MPR technique. Thus, this criterion is not compared with other three applications.

extraserosal invasion, the presence of lymphadenopathies and metastasis were compared among MPR, Quick\_colon, and CutPlane\_colon. MPR technique had the best performance to localize a lesion among these applications. CutPlane\_colon performed less well than MPR and Quick\_colon was the worst. MPR technique also had better performance in demonstrating extraserosal invasion and regional lymph node involvement than CutPlane\_colon application. After pathological correlation, we found MPR images had about 67% positive predictive rate in detecting abnormal regional lymph nodes and the CutPlane\_colon had less than 50%. For the diagnostic performance in surface characterization, Fly-through Navigation had the best score-means and rank-sums. In addition, there was no significant difference between Fly-through Navigation and CutPlane\_colon in this category.

We also divided the entire colon into six short sub-segments: rectum, sigmoid colon, descending

**Table 2.** Comparison of the ability to localizing a lesion in right and left hemicolon in Quick\_colon application:

	Right hemicolon						Left hemicolon	
	C	A	T	D	S	R		p value
Number of lesions	3	7	4	2	13	9		
Score means	0.33	1.57	1.00	3.00	2.31	2.67		
	1.1428					2.5000		< .01

C = cecum; A = ascending colon; T = transverse colon;

D = descending colon; S = sigmoid colon; R = rectum

colon, transverse colon, ascending colon, and cecum. The scores in different colonic segments with the Quick\_colon software were also compared (Table 2). There were significantly higher scores in rectum and descending colon than in other segments. When left hemicolon (rectum, sigmoid colon, and descending colon) and right hemicolon (transverse colon, ascending colon, and cecum) were analyzed separately, we also found that the left hemicolon had higher scores than in right hemicolon.

## DISCUSSION

Our results suggested that MPR technique had the overall best diagnostic performance and Fly-through navigation application was the best for surface depiction. Although CutPlane\_colon technique had both 2D and 3D information on a single image, its 2D information such as extraserosal soft tissue and regional lymph node was not as good as MPR application. It performed better in 3D information when the surface character was evaluated and its performance was even as good as Fly-through Navigation application. The ability of Quick\_colon technique was mainly in localizing a lesion and characterizing the luminal surface but the performance of this application was overall disappointing in our study when compared with other applications. It may be due to superimposition of distended small intestinal loops and insufficient distension.

We found that MPR possessed several advantages in image interpretation: the ability of simultaneous three planes for the same focal findings in a single screen, giving the additional information of enhancement pattern of the lesion, extraluminal infiltration, and regional lymph nodes. Any suspected lesion shown on one plane could be correlated simultaneously with other two different planes. An enhancing lesion could tell a true lesion from non-enhancing fecal material, which might appear the same in Navigation. The presence of extraserosal invasion and regional lymph node involvement indicated the malignant behavior of the lesion. This information largely increased our confidence in diagnosis. In daily practice, MPR for whole colonic segment was reviewed and lesion would be picked up. The other three applications would then be evaluated and correlated. When a suspected lesion which might change position on supine and prone images and/or contained some air-bubbles, fecal material was favored. A true lesion often revealed different extent of "shoulder" appearance, abnormal enhancement, some with extraserosal infiltration, and even regional lymphadenopathy on MPR images. A true lesion would also present as a persistently non-distended focus or segment of colon, with focal asymmetry or circumferential narrowing simulating an apple-core lesion, on Quick\_colon images. A poorly distended segment or a haustral fold should be differentiated in all cases. The former may change in shape on images obtained from different position and the latter often revealed smooth, thin, and circumferential shape. If a suspected lesion had abrupt and irregular mucosal margin, and/or deformity of adjacent haustral fold on Fly-through

Navigation images or CutPlane\_colon images, a true lesion was favored. These pitfalls of differentiation in true lesion from colonic folds, colonic contents, or artifact were also discussed in previous publications [9-10].

The diagnostic performances with post-processing techniques for detecting colorectal polyps with spiral CT colonoscopy were also evaluated in recent studies [11, 12]. Their results showed similar performance in polyp detection among 2D MPR, 3D MPR, and Fly-through Navigation. Individual cases showed improved characterization with 3D MPR or Fly-through Navigation. The difference between these studies and ours may be the use of intravenous contrast medium in our cases. This point is also supported by another recent report [7].

For the diagnostic performance in extraserosal invasion and regional lymph node involvement, MPR technique had significantly higher score-means than CutPlane\_colon application. By slabbing a thick data into oblique axial, coronal, and sagittal images, CutPlane\_colon technique intended to show both the surface/luminal appearance of the lesion and the sectional information on a single image. The window level would encompass a very wide range from that of soft tissue to air. That kind of window contrast and depth were not as good as MPR application on that plane. For the purpose of extraserosal invasion, adjusting a good window level for that section would lose the luminal information.

Although MPR technique had the best diagnostic performance in many ways, the ability to characterize the surface of a lesion was not as good as Fly-through Navigation or CutPlane\_colon applications. The information of mucosal surface was important in diagnosis especially when the suspected mass was adjacent to a colonic fold. An abrupt margin, and/or deformity of adjacent haustral fold on Navigation images or CutPlane\_colon applications may play an important supplementary role in differentiating true lesion.

We found that significant higher scores in rectum and descending colon than in other segments by Quick\_colon application. We also found that the left hemicolon (rectum, sigmoid colon, descending colon) had higher scores than right hemicolon (transverse colon, ascending colon, and cecum). In our experience, the diagnostic performance of Quick\_colon application largely depended on the sufficiency of colonic distention and inversely on the amount of overlapped segment from small intestine. Various amount of small intestinal air in front of right hemicolon as some cases in our study often obscured the demonstration of the lesion at cecum or ascending



colon. Furthermore, redundant transverse colon in some cases may also increase the difficulty of lesion identification. This may explain lower scores in right hemicolon.

Interpretation of all images with all four applications is time-consuming (about 1 to 1.5 hours). We had the opportunity to perform a few cases using a newer version of the GE v.4.0 Workstation. The postprocessing time would be dramatically shortened to 15 to 20 minutes. The surface rendering calculation requires the longest time (about 75%). In general, our results suggest that 2D MPR itself is efficient enough in lesion localization and demonstration. Other three applications served supplementary roles in diagnosis. In order to improve time-efficiency, we suggest that other three 3D applications should be used as a problem solver if the lesion on 2D MPR is not conclusive. This point of view is also supported in one recent study [13]: complete interpretation of 2D MPR and other 3D applications takes significant longer average evaluation time but gives no significant improvement in detection rates.

In conclusions, 2D MPR had overall highest ability in lesion detection and demonstration among post-processing applications. The other three 3D applications serve the supplementary role in diagnosis of colorectal cancer. Although Fly-through Navigation shares competitive score in lesion demonstration, it should be served as a problem solver. We further propose that even a workstation equipped with only 2D MPR could offer enough diagnostic value in colorectal cancer, which saves us both time and money.



## REFERENCES

1. Hara AK. The future of colorectal imaging: computed tomographic colonography. *Gastroenterol Clin North Am.* 2002; 31: 1045-1060
2. McFarland EG, Pilgram TK, Brink JA, et al. CT colonography: multiobserver diagnostic performance. *Radiology* 2002; 225: 380-390
3. Gluecker TM, Fletcher JG. CT colonography (virtual colonoscopy) for the detection of colorectal polyps and neoplasms. current status and future developments. *Eur J Cancer* 2002; 38: 2070-2078
4. Maria HS, Elisabeth S, Anders L, et al. Patient Acceptance of CT Colonography and Conventional Colonoscopy: Prospective Comparative Study in Patients with or Suspected of Having Colorectal Disease. *Radiology* 2002 222: 337-345
5. Ristvedt SL, McFarland EG, Weinstock LB, et al. Patient preferences for CT colonography, conventional colonoscopy, and bowel preparation. *Am J Gastroenterol.* 2003; 98: 578-585
6. Yee J, Hung RK, Akerkar GA, et al. The usefulness of glucagon hydrochloride for colonic distention in CT colonography. *AJR Am J Roentgenol.* 1999; 173: 169-172
7. Martina MM, Richard JF, Jonathan BK, et al. Utility of Intravenously Administered Contrast Material at CT Colonography. *Radiology* 2000; 217: 765-771
8. Chen SC, Lu DS, Hecht JR, et al. CT colonography: value of scanning in both the supine and prone positions. *AJR Am J Roentgenol.* 1999; 172: 595-599
9. Fletcher JG, Johnson CD, MacCarty RL, et al. CT colonography: potential pitfalls and problem-solving techniques. *AJR Am J Roentgenol.* 1999; 172: 1271-1278
10. Macari M, Megibow AJ. Pitfalls of using three-dimensional CT colonography with two-dimensional imaging correlation. *AJR Am J Roentgenol.* 2001; 176: 137-143
11. Judy Y, Geetanjali AA, Raymond KH, et al. Colorectal Neoplasia: Performance Characteristics of CT Colonography for Detection in 300 Patients. *Radiology* 2001; 219: 685-692
12. Elizabeth GM, James AB, Thomas KP, et al. Spiral CT Colonography: Reader Agreement and Diagnostic Performance with Two- and Three-dimensional Image-Display Techniques. *Radiology* 2001; 218: 375-383
13. Macari M, Milano A, Lavelle M, et al. Comparison of time-efficient CT colonography with two- and three-dimensional colonic evaluation for detecting colorectal polyps. *AJR Am J Roentgenol.* 2000; 174: 1543-1549



## 電腦輔助之後處理電腦斷層結腸影像在結腸直腸癌病人之診斷價值

游治維<sup>1</sup> 顧逸康<sup>1</sup> 李崇維<sup>1</sup> 曾旭明<sup>1</sup> 徐劍耀<sup>1</sup> 魏達成<sup>2</sup> 王德宏<sup>3</sup> 翁昭旻<sup>3</sup>

國立台灣大學醫學院附設醫院 影像醫學部<sup>1</sup> 外科部<sup>2</sup> 內科部<sup>3</sup>

本研究的目的是在評估電腦輔助之後處理電腦斷層結腸影像在結腸直腸癌病人之診斷價值。總共34個由傳統內視鏡與／或結腸鉗劑檢查初步診斷為結腸直腸癌的病人，在他們進行手術前接受電腦斷層結腸影像檢查。由螺旋式電腦斷層儀取得影像後，將資料傳至一個獨立的電腦工作站做進一步分析。我們利用一個主觀量表來分析四種後置影像處理軟體用於病灶定位，評估漿膜外侵犯，尋找局部淋巴結腫大，以及表現病灶表面特徵的診斷價值。這四個軟體包括了Multi-planar reconstruction (MPR)，Quick\_colon，CutPlane\_colon，與Fly-through navigation。研究的結果顯示這四種後置影像處理軟體在不同的情形各有其診斷價值：MPR主要能將整段病灶的清楚地顯示出來，並且能利用顯影的型態與漿膜外侵犯的情況來協助診斷。Fly-through navigation則是在用於表現病灶表面特徵時顯得出色。Quick\_colon則利用與傳統結腸鉗劑檢查相似的表現方式來顯現病灶在三維空間的位置。CutPlane\_colon能同時提供二維空間與三維空間的資訊。最後，我們的研究結果顯示在這四種軟體中MPR在多項比較中得到最高的分數。因此，在這四種後置影像處理軟體中，MPR對病灶的定位以及病灶特徵的顯現具有最佳的能力。其他三種軟體則適合扮演輔助的角色。

關鍵詞：結腸直腸癌，電腦輔助之後處理，電腦斷層結腸影像檢查，虛擬結腸鏡

