

Herpes-like virus infection causing mortality of cultured abalone *Haliotis diversicolor supertexta* in Taiwan

Pen Heng Chang^{1,*}, Shu Ting Kuo², San Huei Lai¹, Hong Shii Yang³,
Yun Yuan Ting³, Ching Lung Hsu⁴, Hon Cheng Chen⁵

¹Department of Veterinary Medicine, College of Bio-Resources and Agriculture, National Taiwan University, Taipei 10617, Taiwan, ROC

²National Institute for Animal Health, Tansui 25158, Taiwan, ROC

³Mariculture Research Center, Fisheries Research Institute, Tainan 72453, Taiwan, ROC

⁴Department of Aquaculture and Coastal Fisheries, Council of Agriculture, Taipei 10093, Taiwan, ROC

⁵Department of Zoology, College of Science, National Taiwan University, Taipei 10617, Taiwan, ROC

ABSTRACT: A herpes-like virus is demonstrated for the first time to be associated with high mortality rates in maricultured abalone *Haliotis diversicolor supertexta* in Taiwan. Histopathology of moribund abalone indicated that the nerve system was the primary target tissue. The lesions were characterised by tissue necrosis accompanied with infiltration of haemocytes. Electron microscopic examination demonstrated viral particles within the degenerated cerebral ganglion cells. The viruses were hexagonal, approximately 100 nm in diameter and had a single coat. Some viral particles contained a dense nucleoid, while others were empty. The ultrastructure and morphogenesis of the virus particles were consistent with those of the herpesvirus described from the oyster *Crassostrea virginica*. Experimental infection using supernatant collected from minced visceral organs and muscle of moribund abalone induced 100% mortality through both intramuscular injection and bath treatments.

KEY WORDS: Herpes-like virus · *Haliotis diversicolor supertexta* · Mortality · Pathogenicity

—Resale or republication not permitted without written consent of the publisher—

INTRODUCTION

Herpes-like virus infection in marine bivalves was first observed in adult oysters *Crassostrea virginica* (Farley et al. 1972). Subsequently, this virus has been detected in other oyster species (Hine et al. 1992, Nicolas et al. 1992, Comps & Cochenne 1993, Renault et al. 1994, 2000). Herpesviruses have also been characterised in nonostreid bivalves such as European clam *Ruditapes decussatus* and Manila clam *R. philippinarum* (Renault & Arzul 2001, Renault et al. 2001). Among these viruses, ostreid herpesvirus-1 (OsHV-1) (Minson et al. 2000) and a variant of OsHV-1 (OsHV-1 var) have been analysed by PCR (polymerase chain

reaction), restriction endonuclease digestion of PCR products and DNA sequencing. OsHV-1 and OsHV-1 var are representatives of a single viral species that may be the ubiquitous cause of herpesvirus infections in marine bivalves (Arzul et al. 2001).

Abalones are members of the family Haliotidae and the genus *Haliotis*, having 1-piece shells. Mass mortality of the abalone associated with *Vibrio carchariae* and withering syndrome have been described (Gardner et al. 1995, Nicolas et al. 2002). The aetiological agent of withering syndrome has been identified as a unique taxon, and the provisional status of *Candidatus xenohaliotis californiensis* has been proposed (Friedman et al. 2000). However, the mortality of

*Email: penheng@ntu.edu.tw

abalone caused by herpes-like viruses has not been reported.

The abalone *Haliotis diversicolor supertexta* is a dominant gastropod mollusc used for mariculture in Taiwan. Farms are located in coastal areas around the island. The annual product value of Taiwan abalone exceeds US\$200 million, including US\$58.8 million from those raised in farms along the northeast coast. In January 2003, high mortality of abalone occurred among both land-based and ocean-based ponds in north eastern Taiwan that resulted in losses of US\$11.5 million to the domestic abalone industry. We describe here for the first time a herpes-like virus that infects abalone cultured in Taiwan.

MATERIALS AND METHODS

Animals. Moribund abalone *Haliotis* spp., 5 to 6 cm in shell length, were collected from both land-based and ocean-based farms experiencing increasing mortality on the northeast coast of Taiwan in March 2003. Bacterial isolation was performed from the hepatopancreas, gonad and muscle by inoculating tissue onto Trypticase Soya agar (TSA, Difco) plates and incubating them at 30°C for 24 h.

Histopathology. Samples of visceral organs, muscle and mantle were fixed in 10% neutral formalin, embedded in paraffin, sectioned at 5 µm and stained with Mayer's haematoxylin and eosin (H & E).

Electron microscopy. Two different techniques were applied. For thin-section electron microscopy of paraffin-embedded tissues, cerebral ganglions were retrieved from the paraffin block, deparaffinised and reprocessed for electron microscopy. Then, 1 ml of 2.5% glutaraldehyde (0.1 M cacodylate buffer, pH 7.2) was added to the samples, and they were fixed for 6 h; then they were rinsed and equilibrated 3 times for 10 min each using 0.1 M cacodylate buffer. Osmium tetroxide (0.1 M cacodylate buffer, pH 7.2) at 1% was carefully added to the samples, and they were kept at room temperature for 2 h. Samples were rinsed and equilibrated 3 times for 10 min each using 0.1 M cacodylate buffer, then dehydrated using a gradient series of ethanol at 35, 50, 70, 85, 90, 95 and 100%, for 10 min each. Samples were immersed in a series of ethanol-resin mixtures for 2 h each. The ratio of ethanol to resin was changed from 3:1 to 1:1 to 1:3. Samples were embedded by 100% resin immersion. Then, samples were polymerised for 24 h at 70°C. Thick sections were stained with 1% toluidine blue solution and observed under a light microscope to determine cell morphology. Ultra-thin sections (0.35 µm) were double-stained with 1% uranyl acetate and lead citrate and examined using transmission electron microscopy.

For negative-contrast electron microscopy, samples of visceral organs, muscle and mantle of 10 moribund abalone were pooled, homogenised in phosphate-buffered saline (PBS) to give a 10% (w/v) suspension, and centrifuged at 3000 × *g* for 20 min at 4°C. The supernatant was centrifuged at 100 000 × *g* for 10 min; the pellet was negatively stained with 2% phosphotungstic acid and examined using electron microscopy (Bozzola & Russell 1992, Lipart & Renault 2002).

Preparation of virus solution for the infection trail. Abalone collected from a farm was used for the study. Tissues were removed from moribund abalone, minced, resuspended in MEM and homogenised for 1 to 2 min in a Virtis blender. The homogenate was clarified by centrifugation at 1500 × *g* for 20 min at 4°C. The supernatant fluid was collected and passed through 0.45 µm membrane filters.

Infection trial. The susceptibility of abalone to herpes-like viruses was examined following experimental exposures with the viral supernatant. Three groups of 10 abalone each obtained from a farm in southern Taiwan that had not experienced an epizootic were divided into herpes-like-virus and control groups. Experiments were carried out in 100 l glass aquaria containing 70 l of salt water. Aquaria were aerated by water recirculating through in-tank, glass-wool filters at 17 to 20°C. In the injection group, 10 abalone were intramuscularly (IM) injected with 0.1 ml of supernatant. In the bath group, 10 abalone were bathed in a 500× diluted supernatant for 30 min, and then stocked in separate aquaria. Two control groups were treated by both injection and bathing following the same procedures, but using MEM instead. Mortalities of abalone were recorded daily. Duplicate infection trials have been carried out in this study.

RESULTS

Epidemiological investigation

Commencing in January 2003, mass mortalities of *Haliotis* spp. occurred among cultured abalone in north eastern Taiwan. During the epizootic, the water temperature was 16 to 19°C. Both adult and juvenile abalone suffered from the disease, with cumulative mortalities of 70 to 80%. Death of all of the abalone in a pond can occur within 3 d of the onset of clinical signs. The disease was reported only in *H. diversicolor supertexta*, while cohabitating Japanese black abalone *H. discus* remained normal. The gross appearance of affected abalone revealed mantle recession and muscle stiffness.

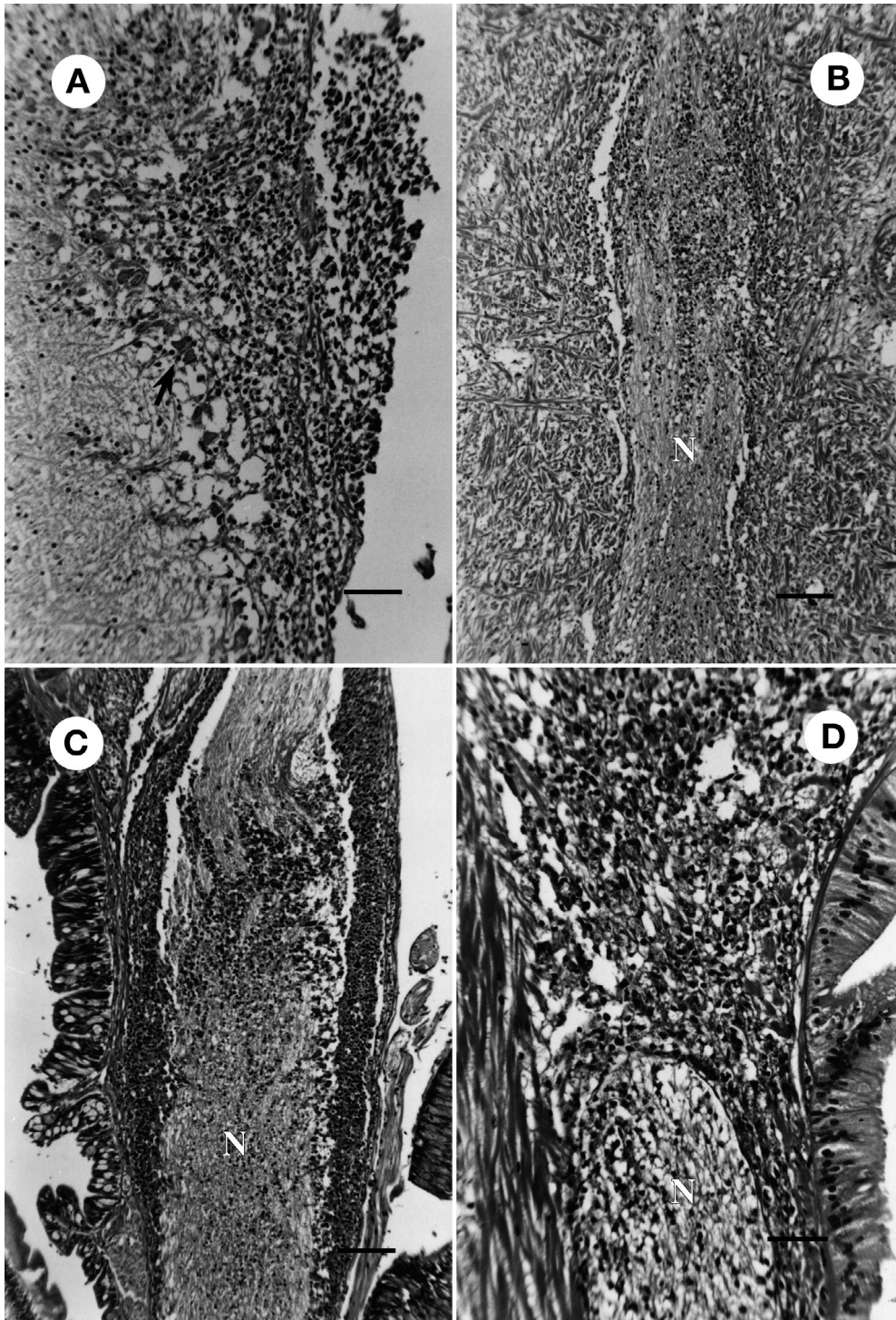


Fig. 1. *Haliotis diversicolor supertexta*. (A) Histological examination of the cerebral ganglion revealing lesions in the cerebral ganglion and surrounding neurilemma. Diffuse necrosis accompanied with infiltration of haemocytes was prominent in the tissue. Degenerated neurosecretory cells (arrow) were noted. Scale bar = 50 μ m. (B) Histological examination of the foot revealed lesions in the nerve (N) and surrounding muscular tissue. Diffuse necrosis accompanied with infiltration of haemocytes was evident. Scale bar = 100 μ m. (C) Histological examination of the oesophagus revealed lesions in the nerve (N) beneath the mucosa. The lesions involved the nerve and surrounding neurilemma. Scale bar = 100 μ m. (D) Histological examination of the intestine revealed lesions in the muscle and adjacent nerve tissue (N) beneath the mucosa. The lesions consisted of diffuse necrosis accompanied with infiltration of haemocytes. Scale bar = 50 μ m

Histopathology

Histological examination of moribund abalone indicated that the nerve system was the primary target tissue. The lesions were characterised by tissue necrosis accompanied with infiltration of haemocytes. Lesions in the cerebral ganglion consisted of diffuse necrosis and prominent infiltration of haemocytes in the parenchyma and surrounding neurilemma (Fig. 1A). Lesions involving nerve tissues and the surrounding muscular tissue in the foot were evident (Fig. 1B). Similar lesions were also noted in the oesophagus (Fig. 1C) and intestine (Fig. 1D). In some cases, diffuse necrosis accompanied with infiltration of haemocytes in the epithelia and underlying lamina propria of branchial filaments was evident. The sloughing off epithelia were deposited in the interlamellar spaces.

Electron microscopy

TEM examination of cerebral ganglions demonstrated viral particles within the degenerated cells (Fig. 2A). The viral particles were hexagonal, 90 to 100 nm in diameter and had a single coat. Some particles contained a dense nucleoid, while others were empty (Fig. 2B). The morphology and size of the viral

particles were most consistent with a herpes-type virus described from the oyster *Crassostrea virginica* (Farley et al. 1972). Negative-contrast electron microscope examination demonstrated viral particles in the pooled tissue. The viral particles were hexagonal, 90 to 100 nm in diameter and had a single coat.

Infection trial

Abalone died at 2 dpi (days post-inoculation) and 3 dpi in the bath treatment, while all abalone died at 2 dpi with the IM-injection treatment. No abalone died in the control groups. Experimentally infected abalone in both IM-injection and bath groups developed lesions similar to those of naturally affected abalone. No macroscopic or microscopic lesions were observed in the 2 noninfected controls. A duplicate infection trail induced similar mortality and pathology in both treatments.

DISCUSSION

Herpes-like virus infections in abalone have not previously been reported. We now describe for the first time a herpes-like virus infection of maricultured

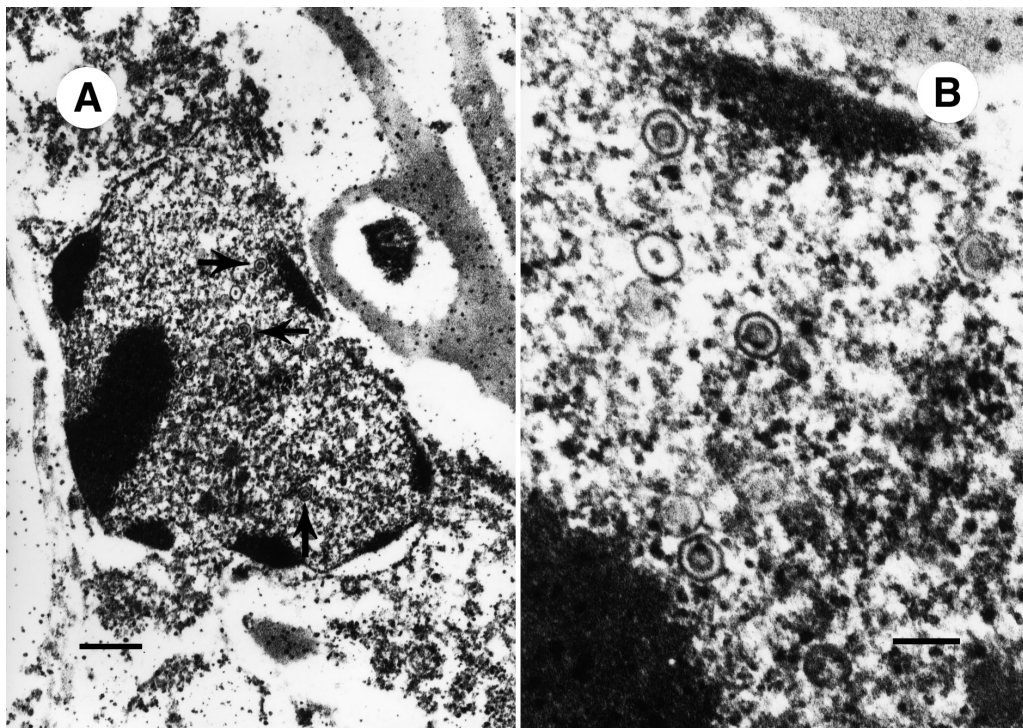


Fig. 2. *Haliotis diversicolor supertexta*. (A) TEM examination of cerebral ganglions showing viral particles (arrows) within degenerated cells. Scale bar = 416 μm . (B) The viral particles were hexagonal, 90 to 100 nm in diameter and had a single coat. Scale bar = 125 μm

abalone *Haliotis diversicolor supertexta* in association with high mortality rates. As the pathology specific to herpes-like virus infection has not been described and no abalone cell line is available to facilitate virus culture, infections were confirmed by detection of virus particles in the lesions and by infection trail.

The herpes-like virus detected in moribund abalone is a cytotoxic virus, with necrosis as its principal pathological effect. The virus caused fatal disease, and exhibited a high degree of neurotropism. Nervous system involvement, affecting the cerebral ganglion and nerve bundles in the muscle of the foot as well as the muscular layers beneath the visceral organ, was noted, although it also induced lesions in other tissues.

Virus replication associated with tissue necrosis in the cerebral ganglion was demonstrated by TEM examination of paraffin-embedded tissues. The morphology and size of the virus particles were similar to those documented previously in the oyster (Farley et al. 1972, Roizman & Baines 1991). The morphological form corresponding to replicating viruses was noted at an intranuclear location. Two classes of nucleocapsids were observed: one with an electron-dense core, which corresponds to DNA-containing capsids, and the other, which lacked the core. Enveloped capsids (virions) were not observed in the cytoplasm, due to destruction of cellular organisms by fixation.

The infection trail following IM-injection and bath treatments demonstrated the high degree of virulence by inducing 100% mortality in abalone. These results demonstrate that the virus induced mortalities and could be transmitted horizontally from infected to healthy abalone using the bath treatment. A pathology similar to that of the field cases was reproduced in the infection trail, and further confirms the tropism of herpes-like viruses for nerve tissues.

The focal origin, high mortality rates and lack of previous events of comparable magnitude suggest that the disease agent was probably an exotic pathogen. It is speculated that this virus was introduced through the importation of juvenile abalone, because a farmer had introduced juvenile abalone from abroad prior to this epizootic. During the epizootic, the highest prevalence was observed during the winter months. The prevalence dropped in the spring and summer periods, possibly because heavily infected individuals died in the winter, and the disease did not begin another cycle of increasing infection until autumn.

Acknowledgements. This study was supported by a grant from the Council of Agriculture, ROC.

LITERATURE CITED

- Arzul I, Renault T, Lipart C, Davison AJ (2001) Evidence for interspecies transmission of oyster herpesvirus in marine bivalves. *J Gen Virol* 82:865–870
- Bozzola JJ, Russell LD (1992) *Electron microscopy: principles and techniques for biologists*. Jones & Bartlett, Boston, MA, p 108–182
- Comps M, Cochenne N (1993) A herpes-like virus from the European oyster, *Ostrea edulis* L. *J Invertebr Pathol* 62: 201–203
- Farley CA, Banfield WG, Kasnic JRG, Foster WS (1972) Oyster herpes-type virus. *Science* 178:759–760
- Friedman CS, Andree KB, Beauchamp KA, Moore JD, Robbins TT, Shields JD, Hedrick RP (2000) '*Candidatus xenohaliotis californiensis*', a newly described pathogen of abalone, *Haliotis* spp., along the west coast of North America. *Int J Syst Evol Microbiol* 50:847–855
- Gardner GR, Harshbarger JC, Lake JL, Sawyer TK, Price KL, Stephenson MD, Haaker PL, Togstad HA (1995) Association of prokaryotes with symptomatic appearance of withering syndrome in black abalone, *Haliotis cracherodii*. *J Invertebr Pathol* 66:111–120
- Hine PM, Wesley B, Hay BE (1992) Herpesvirus associated with mortalities among hatchery-reared larval Pacific oysters, *C. gigas*. *Dis Aquat Org* 12:135–142
- Lipart C, Renault T (2002) Herpes-like virus detection in infected *Crassostrea gigas* spat using DIG-labelled probes. *J Virol Meth* 101:1–10
- Minson AC, Davison A, Eberle R, Desrosiers RC and 5 others (2000) Family Herpesviridae. In: van Regenmortel MHV (ed) *Virus taxonomy: 7th report of the international committee on taxonomy of viruses*. Academic Press, San Diego, p 203–225
- Nicolas JL, Comps M, Cochenne N (1992) Herpes-like virus infecting Pacific oyster larvae, *C. gigas*. *Bull Eur Assoc Fish Pathol* 12:11–13
- Nicolas JL, Basuyaux O, Mazurie J, Thebault A (2002) *Vibrio carchariae*, a pathogen of the abalone *Haliotis tuberculata*. *Dis Aquat Org* 50:35–43
- Renault T, Arzul I (2001) Herpes-like virus infections in hatchery-reared bivalve larvae in Europe: specific viral DNA detection by PCR. *J Fish Dis* 24:161–167
- Renault T, Cochenne N, Le Deuff RM, Chollet B (1994) Herpes-like virus infecting Japanese oyster, *C. gigas* spat. *Bull Eur Assoc Fish Pathol* 14:64–66
- Renault T, Le Deuff RM, Lipart C, Delsert C (2000) Development of a PCR procedure for the detection of a herpes-like virus infecting oysters in France. *J Virol Meth* 88:41–50
- Renault T, Lipart C, Arzul I (2001) A herpes-like virus infects a non-ostreid bivalve species: virus replication in *Ruditapes philippinarum* larvae. *Dis Aquat Org* 45:1–7
- Roizman B, Baines J (1991) The diversity and unity of Herpesviridae. *Comp Immunol Microbiol Infect Dis* 14:63–79