

Frontal Fibrosing Alopecia

-A Case Report

Jin-Bon Hong¹ Sung-Jan Lin^{1,2}

Clinically, frontal fibrosing alopecia (FFA) is characterized by band-like scarring alopecia anterior to the recessed frontotemporal hairline in a progressive course and often accompanied by eyebrow loss. The unique feature of follicular keratosis is often observed at the active margin. Histologically, it resembles lichen planopilaris (LPP). To date, more than 80 cases of FFA have been described in the literature. The majority of FFA was observed in postmenopausal women although this disease has also been found in males and premenopausal females. Hererin, we describe a case of FFA in a premenopausal woman and discuss the differential diagnosis, histopathogenesis, and treatment. FFA is probably an under-recognized alopecia. With increasing reports to delineate this disease, the confusion with other types of alopecia can be avoided. (*Dermatol Sinica* 26: 28-33, 2008)

Key words: Frontal fibrosing alopecia, Premenopausal hair loss

INTRODUCTION

Frontal fibrosing alopecia (FFA) was first proposed by Kossard in 1994 with the term "postmenopausal frontal fibrosing alopecia".¹ FFA is an acquired scarring alopecia presenting as symmetrical recession of frontal and temporal hairlines as well as eyebrow loss. The exact pathophysiology of FFA has not been elucidated and the optimal treatment is still unknown. The majority of the cases are postmenopausal women although this disease has been found in males and premenopausal females.²⁻⁵ Herein, we describe a case of FFA in a premenopausal woman and review the relevant literature.

CASE REPORT

A 46-year-old woman had suffered from progressive frontal hair loss and eyebrow loss for about one year without other associated symptoms before she visited our department. She had a history of rheumatic arthritis, initially presented

with swollen painful joints of fingers 10 years ago. She was initially treated with prednisolone for 2 years and then the rheumatoid arthritis remitted. She denied any other disorders of scalp and hair prior to the onset of hair loss and still had regular menstruation.

Upon examination, symmetrical band-like hair loss was revealed on the frontal and bi-temporal areas (Fig. 1A, 1B, 1C). The frontal hair line was about 4.0 cm above the original level. She also had prominent eyebrow loss bilaterally and was tattooed in these areas for a better cosmetic appearance. The hairless skin in the involved scalp was pale, smooth and slightly shiny without visible follicular orifices and the marginal hair density was decreased. Folliculocentric keratosis was revealed in the remaining hair follicles along the regressed anterior hairline (Fig. 1D). In addition to the scalp and eyebrow hair loss, the patient also had slightly decreased hair density in the axillae, forearms, lower legs

From the Department of Dermatology, National Taiwan University Hospital and College of Medicine¹ and Institute of Biomedical Engineering, National Taiwan University²

Accepted for publication: October 30, 2007

Reprint requests: Sung-Jan Lin, Department of Dermatology, National Taiwan University Hospital, No. 7, Chung-Shan South Road, Taipei, Taiwan.

TEL:886-2-23562141 FAX:886-2-23934177 E-mail: drsjlin@ntu.edu.tw

and the pubic area.

In her laboratory studies, complete blood count, serum ferritin level and thyroid function test were within normal ranges. The test of VDRL gave a negative result. The serum hormone levels of estradiol and testosterone were within normal ranges. Rheumatoid factor was examined two years prior to the onset of alopecia and revealed the following results: RF-IgM 47.3 U/ml (reference range: 1.3~12.0), RF-IgG 37.4 U/ml (reference range 1.3~50), and RF-IgA 12.5 (reference range 3.0~15.0).

Four-mm punch biopsies were obtained from her frontal hair line for direct immunofluorescence and histology examinations. The direct immunofluorescence study gave a negative result. The histology showed a lichenoid perifollicular lymphocytic infiltration around infundibulum and isthmus of hair follicles with focal basal vacuolar change of the outer root sheath (Fig. 2). Scattered eosinophilic necrosis of cells in the outer root

sheath was discernible. There were also infundibular dilatation and follicular hyperkeratosis. The eccrine glands were generally spared. There was neither interfollicular epidermal change nor intense interfollicular dermal inflammation. The horizontal section revealed perifollicular inflammation with mild lamellar fibrosis. Based on the clinical and histological findings, frontal fibrosing alopecia was diagnosed. Topical treatment with 2% minoxidil solution twice daily was given for 4 months but failed to stop the progression of frontal hair loss. Then, oral finasteride (2.5mg/day) was administered to prevent further hair loss.

DISCUSSION

Frontal fibrosing alopecia (FFA), a distinctive pattern of frontal hair loss, was first reported by Kossard in 1994 using the term "postmenopausal frontal fibrosing alopecia".¹ To date, more

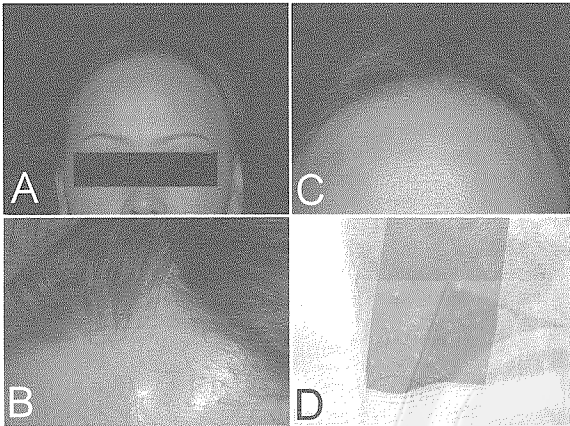


Fig. 1

(A, B, C) Band-like symmetrical hair loss was noted on the frontal and bi-temporal areas with prominent eyebrow involvement (cosmetic tattoos on the eyebrow areas were present). The hairless scalp skin was pale, smooth, and slightly shiny. The follicular orifices anterior to the frontal hairline were obviously diminished. (D) Folliculocentric keratosis can be more clearly appreciated along the shaved regressing hairline before the biopsy.

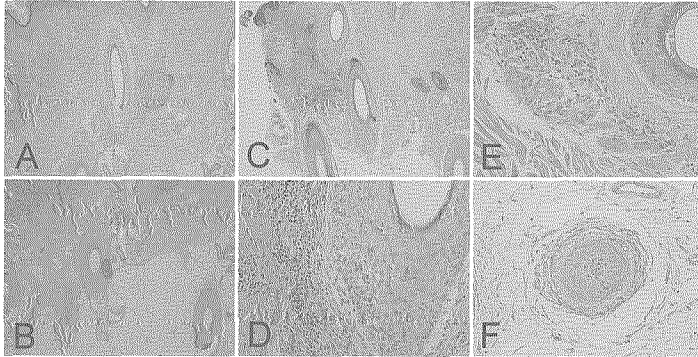


Fig. 2

(A, B, C) There was lichenoid interface infiltration around the isthmus and infundibulum, sparing the lower part of the follicle and hair bulb. (H&E, original magnification x40) (D) Lymphocytic lichenoid infiltration around the isthmus and infundibulum was decernible with focal basal vacuolar degeneration and scattered dyskeratosis. (H&E, original magnification x200) (E) The horizontal section in the dermis revealed perifollicular inflammation with mild lamellar fibrosis. (H&E, original magnification x200) (F) The inflammatory process does not extend to the lower part of the follicle in the subcutis. (H&E, original magnification x200)

than 80 cases of FFA have been described in the literature.⁵⁻¹⁰ The majority of the cases were postmenopausal women.²⁻⁵ FFA is a band-like cicatricial alopecia characterized by symmetrical frontotemporal hairline recession. Although the presence of scarring is typical of FFA, this scarring may be less remarkable than the other cicatricial alopecia. Follicular keratosis with variable perifollicular erythema is usually found at the active margin of hair loss. Prominent loss of eyebrows is often associated with FFA.^{2,5} There is variable hair loss on other body parts, including axillae, extremities, and pubic area. To our knowledge, only one Asian patient of Korean ethnicity has been described in the English literature.¹¹ The rarity of reported cases from Asia may be due to either under-recognition of this disease or an ethnic difference.

Histologically, FFA is featured by lichenoid lymphocytic infiltration around the upper portion of the follicle with focal basal vacuolar degeneration and individual cell necrosis in the outer root sheath. Infundibular dilatation and follicular

hyperkeratosis on histological examination can be prominent, corresponding to clinical follicular keratosis. Perifollicular lamellar fibrosis can be seen in late-stage lesions. The interfollicular epidermis in FFA is always devoid of the lichenoid inflammation, which is commonly present in lichen planopilaris (LPP).¹⁰ The interfollicular dermis and eccrine glands remain uninvolved.^{1,10} The histological findings in our case showed these typical features mentioned above with mild perifollicular fibrosis (Fig. 2). Normally, remarkable perifollicular lamellar fibrosis will develop at a late stage following the lichenoid inflammation.

Due to the histological similarities, FFA is commonly considered a variant of LPP in a number of reports. However, Poblet *et al.* indicated that, compared with LPP, FFA tended to show less inflammation around the infundibulum and isthmus, less superficial perivascular lymphohistiocytic infiltrate and less interfollicular lichenoid changes.¹⁰ Still, it is unlikely to differentiate between FFA and LPP based on the

histological findings alone. Furthermore, the site and stage of the sampled lesion will affect the histological results. Thus, the major difference is determined on the clinical ground. Both LPP and FFA are characterized by perifollicular erythema and follicular keratosis clinically but the unique distribution of hair loss is only present in FFA.^{6,10} Additionally, patients with FFA do not have other mucocutaneous lichenoid lesions as frequently as with LPP.^{4,10,12}

Though distinctive clinically, FFA may sometimes be confused with non-scarring alopecia, such as telogen effluvium, androgenetic and alopecia areata.^{2,5} Unlike FFA, non-cicatricial alopecia preserves follicular orifices. Further, androgenetic alopecia does not cause eyebrow loss and hair miniaturization is not a feature of FFA.⁵ The frontal hairline is usually preserved in androgenetic alopecia in women. Although FFA most frequently occurs in women, male patients have been described in the literature.⁸ The Hamilton-type hair loss of male androgenetic alopecia can easily be distinguished from FFA by the presence of hair miniaturization, relative preservation of central frontal hair line, slow disease progression and lack of follicular erythema and keratosis.

Alopecia areata can also present with sudden-onset and progressive hair loss with or without eyebrow involvement. However, the fibrosing nature, follicular signs of erythema and keratosis are not supposed to appear in alopecia areata. Of note is the ophiasis variant of alopecia areata, in which hair loss can extend from posterior and bitemporal scalp to the frontal area symmetrically. Although FFA rarely involves the occipital scalp, some patients who do not have prominent follicular signs may be misdiagnosed as ophiasis variant alopecia areata.¹³ A skin biopsy is of great help for a correct diagnosis in this condition. Alopecia areata is characterized by peri-bulbar lymphocytic inflammation with follicular miniaturization and telogen arrest. By comparison, the hallmark of FFA is lichenoid interface infiltration around the isthmus and infundibulum, sparing the lower third of the follicle and hair bulb. In the late stage, alopecia areata can make follicles reduced and replaced by fibrous tracts but FFA will

lead to perifollicular lamellar fibrosis.

In other cicatricial alopecic diseases, the neutrophilic types are usually quite inflamed clinically. Among the lymphocytic types of cicatricial alopecia, discoid lupus erythematosus (DLE) usually presents as patchy erythema followed by scarring or depression. The pathological features of interfollicular interface dermatitis, deep perifollicular infiltration and perieccrine inflammation can help to distinguish DLE from FFA. The direct immunofluorescence study of DLE lesions at times shows granular deposition of IgG, IgM and C3 along the epidermal and follicular basal membrane zone, which is not present in FFA as in our case.²

The treatment of FFA is difficult. It is recalcitrant to topical minoxidil solution treatment. The responses to plaquenil and either topical, intralesional, or systemic corticosteroids are variable or limited. Due to the age of onset and patterned hair loss on the frontal area, androgen hormone is a suspected etiology of FFA although no proof of hormone abnormality has been shown.² Finasteride 2.5 mg per day was reported to be able to stabilize frontal recession in some cases.⁶ Whether finasteride is indeed superior to the other treatment is not known. Our patient was put on oral finasteride 2.5 mg per day after the treatment failure of topical 2% minoxidil solution. The patient is now followed up in our department.

REFERENCES

1. Kossard S: Postmenopausal frontal fibrosing alopecia. Scarring alopecia in a pattern distribution. *Arch Dermatol* 130: 770-774, 1994.
2. Kossard S, Lee MS, Wilkinson B: Postmenopausal frontal fibrosing alopecia: a frontal variant of lichen planopilaris. *J Am Acad Dermatol* 36: 59-66, 1997.
3. Zinkernagel MS, Trueb RM: Fibrosing alopecia in a pattern distribution: patterned lichen planopilaris or androgenetic alopecia with a lichenoid tissue reaction pattern? *Arch Dermatol* 136: 205-211, 2000.
4. Faulkner CF, Wilson NJ, Jones SK: Frontal fibrosing alopecia associated with cutaneous lichen planus in a premenopausal woman. *Australas J Dermatol* 43: 65-67, 2002.
5. Moreno-Ramirez D, Camacho Martinez F: Fron-

- tal fibrosing alopecia: a survey in 16 patients. *J Eur Acad Dermatol Venereol* 19: 700-705, 2005.
6. Tosti A, Piraccini BM, Iorizzo M *et al.*: Frontal fibrosing alopecia in postmenopausal women. *J Am Acad Dermatol* 52: 55-60, 2005.
 7. Mirmirani P, Willey A, Headington JT, *et al.*: Primary cicatricial alopecia: histopathologic findings do not distinguish clinical variants. *J Am Acad Dermatol* 52: 637-643, 2005.
 8. Kossard S, Shiell RC: Frontal fibrosing alopecia developing after hair transplantation for androgenetic alopecia. *Int J Dermatol* 44: 321-323, 2005.
 9. Clark-Loeser L, Latkowski JA: Frontal fibrosing alopecia. *Dermatol Online J* 11: 6, 2005.
 10. Poblet E, Jimenez F, Pascual A, *et al.*: Frontal fibrosing alopecia versus lichen planopilaris: a clinicopathological study. *Int J Dermatol* 45: 375-380, 2006.
 11. Lee WS, Hwang SM, Ahn SK: Frontal fibrosing alopecia in a postmenopausal woman. *Cutis* 60: 299-300, 1997.
 12. Mehregan DA, Van Hale HM, Muller SA: Lichen planopilaris: clinical and pathologic study of forty-five patients. *J Am Acad Dermatol* 27: 935-942, 1992.
 13. Kwong RA, Kossard S: Alopecia areata masquerading as frontal fibrosing alopecia. *Australas J Dermatol* 47: 63-66, 2006.



前額纖維化禿髮

-病例報告

洪楨邦¹ 林頌然^{1,2}

國立台灣大學醫學院皮膚科與附設醫院皮膚部¹

國立台灣大學醫學工程研究所²

「前額纖維化禿髮」的臨床特徵是發生於前額至兩側鬚部之進行性帶狀疤痕性禿髮，常伴隨眉毛掉髮。在掉髮活性高的邊緣地帶常可以見到具特色之毛孔角化。此病症之組織學變化則與毛孔扁平苔癬類似。直至今日，全世界已有超過80個案例被報告，其中大部分的前額纖維化禿髮發生於停經之女性，但亦可發生於停經前之女性，甚至是男性都會被報告過。在此，我們報告一例發生於停經前女性之前額纖維化禿髮並討論此疾病的鑑別診斷、組織病理學變化及其治療。前額纖維化禿髮是一種以往較少被辨認出的禿髮疾病，隨著越來越多相關的報告來描繪此疾病，應該可以避免將前額纖維化禿髮與其它禿髮的診斷混淆。(中華皮誌 26: 28-33, 2008)

